

Title	Three-dimensional analysis of pulp chambers in maxillary second deciduous molars
Author(s) Alternative	Amano, M; Agematsu, H; Abe, S; Usami, A; Matsunaga, S; Suto, K; Ide, Y
Journal	Journal of dentistry, 34(7): 503-508
URL	http://hdl.handle.net/10130/53
Right	

Three-dimensional analysis of pulp chambers in maxillary second deciduous molars

M. Amano^a, H. Agematsu^a, S. Abe^a, A. USAMI^b, S. Matsunaga^a, K. Suto^a, Y. Ide^a

^aDepartment of Anatomy, Tokyo Dental College, Chiba, Japan

**^bDivision of Oral Anatomy, Department of Morphological Biology, Ohu University
School of Dentistry, Kohriyama, Japan**

Short title : 3D analysis of pulp chamber on deciduous molar

Keywords: Deciduous molar, Micro-CT, Pulp chamber, Crown contour,

Three-dimensional observation

The corresponding author: Hiroko Agematsu, D.D.Sc.

Department of Anatomy, Tokyo Dental College, 1-2-2 Masago Mihama-ku Chiba,

261-8502 JAPAN

TEL No. : +81-43-270-3759

FAX No. : +81-43-277-4010

E-mail address: agematsu@tdc.ac.jp

Three-dimensional analysis of pulp chambers in maxillary second deciduous molars

Summary

Objective. The purpose of this study was to clarify the positional relationship between the crown contour and the pulp chamber using micro-CT system for restorations of maxillary second deciduous molar.

Methods. Five maxillary second deciduous molar teeth each from the deciduous dentition and the mixed dentition periods were used. The positional relationship between the crown contour and pulp chamber was 3-dimensionally observed by micro-CT. In addition, the thickness of the dentin at each of the pulp horns and the volume ratio of the pulp chamber against the whole crown were measured.

Results. In relationship to the crown contour and the pulp chamber, the pulp horn of the mesiobuccal cusp showed greatest protrusion and eminent swelling of its mesial wall in both the deciduous dentition and the mixed dentition periods. Furthermore, the pulp chamber was shifted to the mesial side. The volume ratio of the pulp chamber to the whole crown, the ratio in the mixed dentition period showed to be significantly smaller than in the deciduous dentition period. The dentin thickness at the mesiobuccal pulp horn was the thinnest.

Conclusions. These results suggest that in preparation of cavities in maxillary second deciduous molars, care is necessary not to expose of the mesiobuccal pulp horn. Especially, the mesial wall of the mesiobuccal pulp horn should be noted.

Introduction

It has been reported that the deciduous tooth as compared to the permanent tooth has a pulp that takes up a larger volume of the crown and that the enamel of the deciduous teeth is thinner.¹ When coronal restorations are planned, it is desirable to make cavity preparations without pulp exposure. It is important to have a three-dimensional image allowing accurate understanding of the morphological characteristics of the deciduous tooth crown, the topographic relationships between the pulp horns and crown contour and the distance between the pulp horns and the crown surface, namely the thickness of the hard tissues.

There have been reports on the topographic relationship between the contour of the crown and the pulp chamber,^{2,3} but observations have been limited to morphological observations using radiographs and sliced specimens.^{4,5} Reports on 3-dimensional observations and structural calculations do exist, but these studies use methods in which a continuous series of slides is prepared, light microscopically examined and then reconstructed.⁶⁻⁹ This technique is destructive and causes material loss in preparation; it is difficult to achieve accurate morphological reconstruction and evaluations.

As an alternative and refined approach, we made 3-dimensional observations on the morphology of the surface and the interior of the deciduous molar crown using the microcomputerised tomography (micro-CT), which allows non-destructive and flexible 3-dimensional observations with quality structure analysis. This study was focused on the morphology of the pulp chamber; especially the morphology of the pulp horns and their

topographic relationships to the crown contour of the maxillary second deciduous molar in the deciduous dentition and the mixed dentition periods. We attempted morphological analysis and made objective evaluations.

Materials and Methods

Preparation of teeth

Ten caries free maxillary second human deciduous molar teeth extracted from dried skulls of Indian children were examined. Five of the teeth were in the deciduous dentition period (the dentition in which ABCDE has reached the occlusal line) and five were in the mixed dentition period (the dentition in which 1BCDE6 has reached the occlusal line).

Micro-CT scanning

The micro-CT system (HMX-225 Actis 4, TESCO, Tokyo, Japan) consists of the main imaging apparatus and the computer which performs the calculations. The main imaging apparatus consists of an X-ray generator and a 360 degree rotating specimen stage and a detector. In photographing, the tooth specimen was placed with the tooth axis vertical to the platform. The tube voltage was set at 80kV, the tube current at 70uA, the focal spot size of the X-ray generator at 5um and magnification at x4. The detector was equipped with an image intensifier tube measuring 4 inches and a 1 inch CCD camera with a scanning line of 1024 x 1024 dots/ 16 bits per memory. The camera was capable of outputting 500 bits of raw data. Based on the raw data obtained, 2-dimensional slide

images were produced by the back projection method.

3D reconstruction

Three-dimensional reconstruction was performed using 600 of these 2-dimensional images processed by the volume rendering method. On these 3-dimensional images, arbitrary planes parallel to the tooth axis were simulated. The pulp chamber were extracted and observed from various directions.

Furthermore, the pulp chamber was extracted on the sliced data and stained. By making the enamel and dentin translucent and layering these data, the positional relationship between the crown contour and the pulp chamber was 3-dimensionally observed.

Quantitative shape analysis

In order to make objective evaluations on the topographic relationship between the crown contour and the pulp chamber, the volumes of the total crown, the pulp chamber were each calculated using the analysis soft AVS (K.G.T. Inc.). The volume ratio of the pulp chamber to the total crown was obtained. Furthermore, to understand the dentin width at the pulp horn, arbitrary planes running through the pulp horns which were parallel to the tooth axis were drawn in the reconstructed 3-dimensional images and morphological analysis were made to measure the distance between each pulp horn and the enamel-dentin interface.

Statistical significant differences of the results were examined in two dentition groups

with Mann-Whitney's U test. The significance level was set at $p < 0.05$.

Results

Morphological observations of the maxillary deciduous molar tooth crown in the deciduous dentition and the mixed dentition periods showed that the apices of the cusps in the mixed dentition period were more rounded as compared to the ones in the deciduous dentition period. Furthermore, in the mixed dentition period, the difference in the height between the buccal cusp and the lingual cusp had decreased (Fig.1 a, b Fig.2 a, b).

Observation of the pulp chamber revealed a clear morphological image of the mesiobuccal, distobuccal, mesiolingual and distolingual pulp horns. Furthermore, under the mesiolingual cusp, a pulp horn corresponding to Carabelli's cusp was seen. In the deciduous dentition period, the mesiobuccal pulp horn was the most projecting, followed by the distobuccal, the mesiolingual and the distolingual pulp horns (Fig.3 a, b). In the mixed dentition period, the mesiolingual and distobuccal pulp horns had become less prominent. The mesiolingual pulp horn was clearly rounded at their tips (Fig.4 a, b).

In order to obtain a 3-dimensional topographic relationship of the crown contour and the pulp chamber, the setting was adjusted so that pulp chamber was non-translucent and the enamel and the dentin, the hard tissues, were translucent. As a result, the mesiobuccal pulp horn was the most prominent and the eminent swelling of its mesial wall was observed in both the deciduous dentition (Fig.5) and the mixed dentition periods (Fig.6).

In addition, the pulp chamber had shifted to the mesial in relationship with the crown contour.

The volume ratios of the pulp chamber in the deciduous and the mixed dentition periods were $9.6\pm 0.5\%$ and $8.1\pm 0.6\%$. The ratio in the mixed dentition period showed a significant decrease compared with deciduous dentition period (Mann-Whitney's U test $p<0.05$) (Fig.7).

In order to clarify the location of the minimum dentin thickness, we measured the dentin thickness all pulp horns in the deciduous and the mixed dentition periods. The thickness of the dentin was 1.5mm-2.4mm in the deciduous dentition period and 1.5-2.8mm in the mixed dentition period. In both dentition periods, there was a tendency that the thickness at the buccal pulp horns was thinner than the one at the lingual pulp horns. In addition, the thinnest location in both dentition periods was the mesiobuccal pulp horn. Significant differences were noted between the mesiobuccal pulp horn and other regions in the dentin thickness (Mann-Whitney's U test $p<0.05$) (Fig.8).

Discussion

Until now, the interior of a tooth had been studied by means of X-rays, transparent tooth models and serial sections.^{4,5,10,11} Lyroudia et al.,⁷⁻⁹ Mikrogeorgis et al¹¹ and Nozaka et al.¹² have prepared serial sections, traced the contour of the tooth and the pulp chamber and by layering the traces, obtained a 3-D reconstruction. But, this method has cutting margin problems and a perfect reconstruction figure could not be obtained. In order to

solve these problems, the micro-CT, this has recently been developed and has begun to be used for observations of the inner morphology of the bone and tooth, was applied to this study. The micro-CT is non-destructive and allows for observations and analysis from any angle. Studies using the micro-CT have started to be used in many fields of clinical dentistry.¹³⁻²² It is thought to be especially useful in studying the morphology of pulp cavity which can not be directly observed by the naked eye.

Two-dimensional image obtained from the micro-CT distinguishes the difference in level of calcification as difference in X-ray translucency. In addition, it analyzes the difference as 16 bits gray scale data. This allows for the clear discrimination of the enamel, dentin and pulp cavity. Furthermore, these three parts were separately 3D reconstructed. The images of the 3-D reconstruction are possible to observe from various directions. For this reason, we were able to clearly observe the pulp horn in Carabelli's cusp and the eminent swelling of mesial wall in mesiobuccal pulp horn, which showed the dull image in X-ray film.

The pulp morphology of the maxillary second deciduous molar has been studied by Nozaka et al.¹² Their method was to layer the sliced specimens in order to obtain a 3-D reconstruction and analysis had been made. But the dental period of the specimen has not been indicated. We assume that depending on when the tooth erupted and when it started to occlude, the crown contour and the morphology of the pulp chamber within will differ. Therefore, in this study, by observing the maxillary deciduous molar in both the deciduous dentition period and the mixed dentition period, we were able to clarify the morphological change of the crown contour and pulp chamber morphology.

The volume ratio of the pulp chamber in the mixed dentition period was significantly smaller. The mixed dentition period that we chose in this study was at a stage when the permanent first molar and the permanent central incisor had reached the occlusal line. In other words, deciduous second molars in which attrition had not reached the dentin were selected as specimen. Even under this condition, the volume ratio of the pulp chamber in the mixed dentition period was smaller. The reasons we thought were because 1) the systematic growth of secondary dentin observed almost throughout the pulp chamber is rapid in deciduous teeth. 2) When attrition is present, regardless of it reaching the dentin or not, the odontoblasts are stimulated, leading to deposition of tertiary dentin at the pulp horn. From these observations we hypothesize that the growth of secondary and tertiary dentin over pulp horns exceeds the reduction of enamel due to attrition.

To further study this theory, we observed the thickness of dentin at the pulp horns in the deciduous dentition and the mixed dentition periods. Unless the attrition reaches the dentin, the position of the enamel-dentin interface is constant. Therefore in this study, we measured the distance from the pulp horn to the dentino-enamel junction in both dentition periods and compared the results. Our measurements showed that the width at the mesiobuccal pulp horn was the least, measuring approximately 1.5mm and this measurement was similar in both the deciduous dentition and the mixed dentition periods.

The maxillary second deciduous molar has a crown contour similar to that of the permanent maxillary first molar. However, the cervical area is distinctly narrowed and the buccal plane shows dramatic lingual curving, resulting in an occlusal surface which is

comparatively small. The mesial shifting of the pulp chamber observed in the maxillary second deciduous molar with regards the topographic relationship between the crown contour and the pulp chamber is understood to be related to this morphologic characteristic. The dentin thickness at the mesiobuccal pulp horn was similar in both the deciduous and mixed dentition periods.

Conclusions

From observations made on the topographic relationship between the crown contour and the pulp chamber in the maxillary second deciduous molar teeth, it is clear that the pulp is shifted to the mesial position in relationship to the crown contour. Furthermore, there was a clear tendency for the mesiobuccal pulp horn to show a strong occlusal protrusion and the eminent swelling of its mesial wall in both the deciduous dentition and the mixed dentition periods.

Acknowledgements

We thank Dr Samuel W. Oglesby (Division of Surgical, Therapeutic and Bioengineering Sciences, Department of Clinical Dentistry, University of Southern California School of Dentistry, USA) for valuable suggestions.

References

1. Ash MM, Nelson SJ. Wheeler's Dental Anatomy, Physiology, and Occlusion, 8th ed. Philadelphia: Elsevier Science, 2003.
2. Philippas GG. Influence of occlusal wear and age on formation of dentin and size of pulp chamber. *Journal of Dental Research* 1961; **40**: 1186-98.
3. Kandemir S. The radiographic determinability of the distance between the pulp horns in the permanent first and second molar teeth. *Journal of Oral Science* 1998; **40**: 143-6.
4. Chandler NP. The radiographic assessment of pulp size: validity and clinical implications. *New Zealand Dental Journal* 1989; **85**: 23-6.
5. Chandler NP, Pitt Ford TR, Monteith BD. Coronal pulp size in molars: a study of bitewing radiographs. *International Endodontic Journal* 2003; **36**: 757-63.
6. Kimura O, Dykes E, Fearnhead RW. The relationship between the surface area of the enamel crowns of human teeth and that of the dentine-enamel junction. *Archives of Oral Biology* 1977; **22**: 677-83.
7. Lyroudia K, Mikrogeorgis G, Nikopoulos N, Samakovitis G, Molyvdas I, Pitas I. Computerized 3-D reconstruction of two "double teeth". *Endodontics and Dental Traumatology* 1997; **13**: 218-22.
8. Lyroudia K, Pantelidou O, Mikrogeorgis G, Chatzikallinikidis C, Nikopoulos N, Pitas I. The use of 3D computerized reconstruction for the study of coronal microleakage. *International Endodontic Journal* 2000; **3**: 243-7.

9. Lyroudia K, Mikrogeorgis G, Bakaloudi P, Kechagias E, Nikolaidis N, Pitas I. Virtual endodontics: Three-dimensional tooth volume representations and their pulp cavity access. *Journal of Endodontics* 2002; **28**: 599-602.
10. Kelsen AE, Love RM, Kieser JA, Herbison P Root canal anatomy of anterior and premolar teeth in Down's syndrome. *International Endodontic Journal* 1999; **2**: 211-6.
11. Mikrogeorgis G, Lyroudia KL, Nikopoulos N, Pitas I, Molyvdas I, Lambrianidis TH. 3D computer-aided reconstruction of six teeth with morphological abnormalities. *International Endodontic Journal* 1999; **32**: 88-93.
12. Nozaka K, Itoh M, Ono R, Satoh T, Amari E, Nozaka Y, Hongoh T. New cavity forms in second deciduous molars which maximize dentin thickness between cavity and pulp chamber. *The Bulletin of Tokyo Dental College* 1990; **31**: 309-19.
13. Nielsen RB, Alyassin AM, Peters DD, Carnes DL, Lancaster J. Microcomputed tomography: An advanced system for detailed endodontic research. *Journal of Endodontics* 1995; **21**: 561-8.
14. Dowker SEP, Davis GR, Elliott JC, Wong FSL. X-ray microtomography: 3-dimensional imaging of teeth for computer-assisted learning. *European Journal of Dental Education* 1997; **1**: 61-5.
15. Dowker SEP, Davis GR, Elliott JC. X-ray microtomography, Nondestructive three-dimensional imaging for in vitro endodontic studies. *Oral Surgery oral Medicine Oral Pathology* 1997; **83**: 510-6.
16. Bjørndal L, Carlsen O, Thuesen G, Darvann T, Kreiborg S. External and internal

- macromorphology in 3D-reconstructed maxillary molars using computerized X-ray microtomography. *International Endodontic Journal* 1999; **32**: 3-9.
17. Rhodes JS, Ford TRP, Lynch JA, Liepins J, Curtis RV. Microcomputed tomography: a new tool for experimental endodontology. *International Endodontic Journal* 1999; **32**: 165-70.
18. Bergmans L, Cleynenbreugel JV, Wevers M, Lambrechts P. A methodology for quantitative evaluation of root canal instrumentation using microcomputed tomography. *International Endodontic Journal* 2001; **34**: 390-8.
19. Peters OA, Schönenberger K, Laib A. Effects of four Ni-Ti preparation techniques on root canal geometry assessed by micro computed tomography. *International Endodontic Journal* 2001; **34**: 221-30.
20. Verdonschot N, Fennis WMM, Kuijs RH, Stolk J, Kreulen CM, Creugers NHJ. Generation of 3-D finite element models of restored human teeth using micro-CT techniques. *The International Journal of Prosthodontics* 2001; **14**: 310-5.
21. Oi T, Saka H, Ide Y. Three-dimensional observation of pulp cavities in the maxillary first premolar tooth using micro-CT. *International Endodontic Journal* 2004; **37**: 46-51.
22. Efeoglu N, Wood D, Efeoglu C. Microcomputerised tomography evaluation of 10% carbamide peroxide applied to enamel. *Journal of Dentistry* 2005; **33**: 561-7.

Figure legends

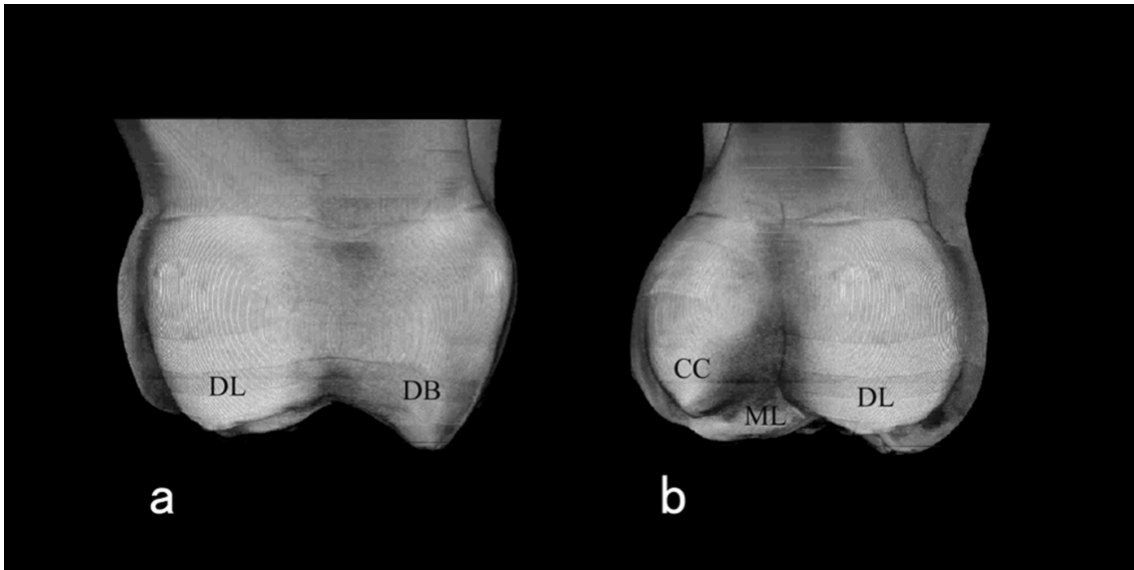


Figure 1 3D rendered image of external crown morphology of maxillary second deciduous molar in the deciduous dentition.

(a) Distal aspect; (b) Lingual aspect.

DL: distolingual cusp DB: distobuccal cusp ML: mesiolingual cusp CC: Carabelli's cusp

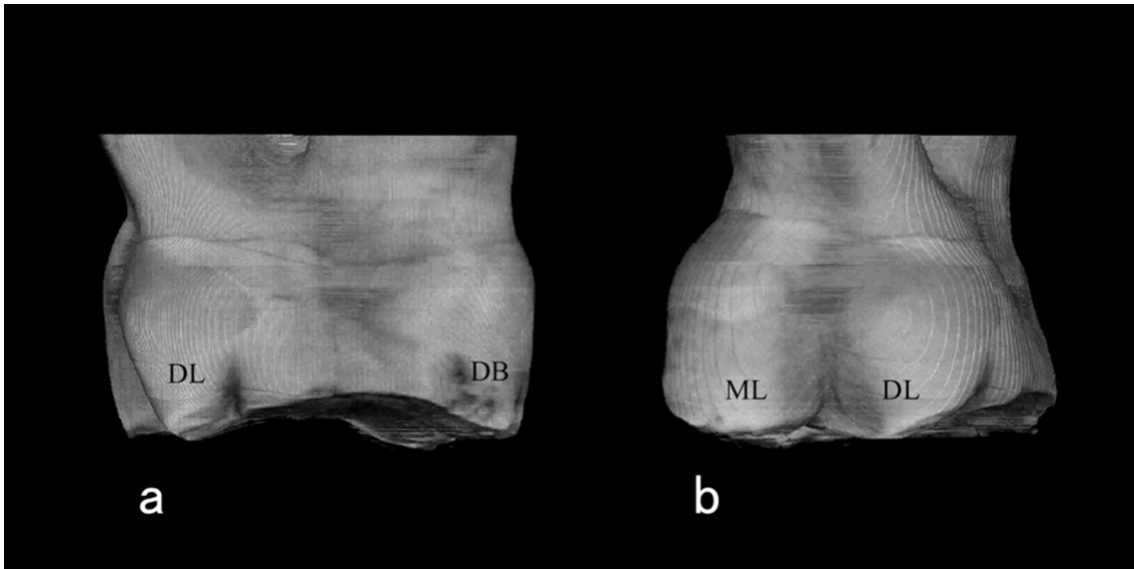


Figure 2 3D rendered image of external crown morphology of maxillary second deciduous molar in the mixed dentition.

(a) Distal aspect; (b) Lingual aspect.

DL: distolingual cusp DB: distobuccal cusp ML: mesiolingual cusp

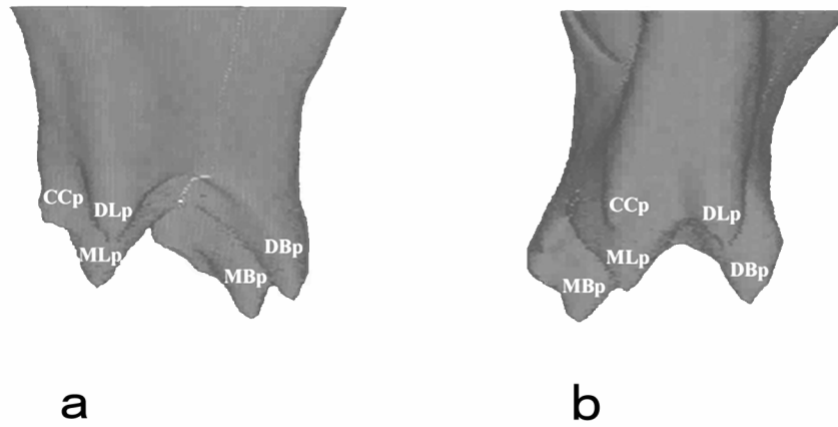


Figure 3 3D rendered image of pulp chamber morphology of maxillary second deciduous molar in the deciduous dentition.

(a) Distal aspect; (b) Lingual aspect.

DLp: distolingual pulp horn DBp: distobuccal pulp horn MLp: mesiolingual pulp horn MBp: mesiobuccal pulp horn CCp: pulp horn of Carabelli's cusp

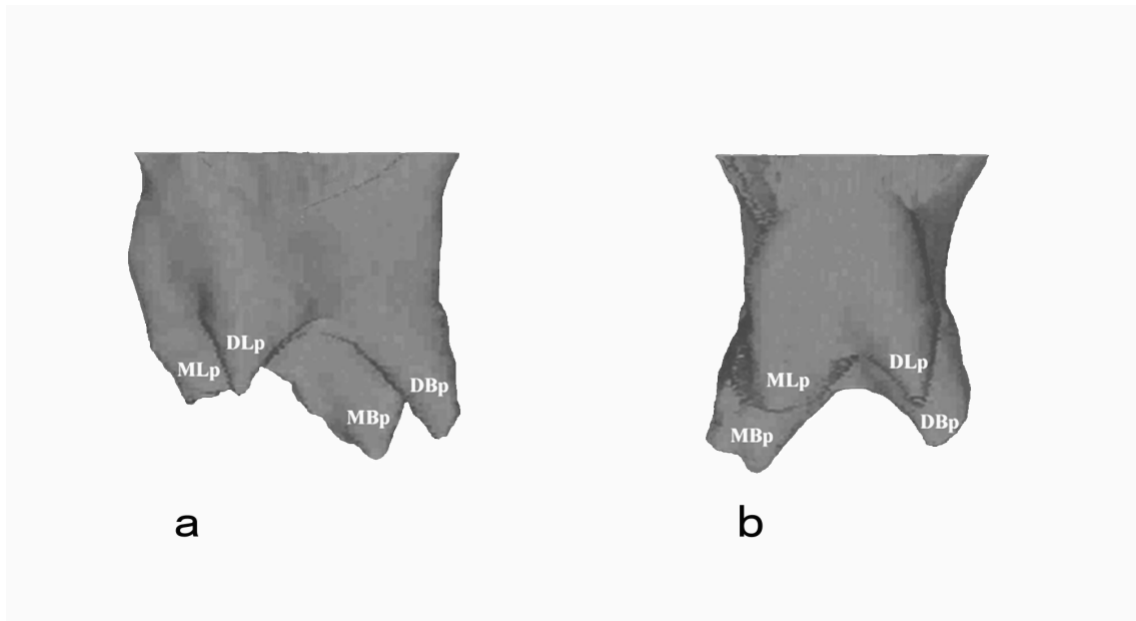


Figure 4 3D rendered image of pulp chamber morphology of maxillary second deciduous molar in the mixed dentition.

(a) Distal aspect; (b) Lingual aspect.

DLp: distolingual pulp horn DBp: distobuccal pulp horn MLp: mesiolingual pulp horn MBp: mesiobuccal pulp horn

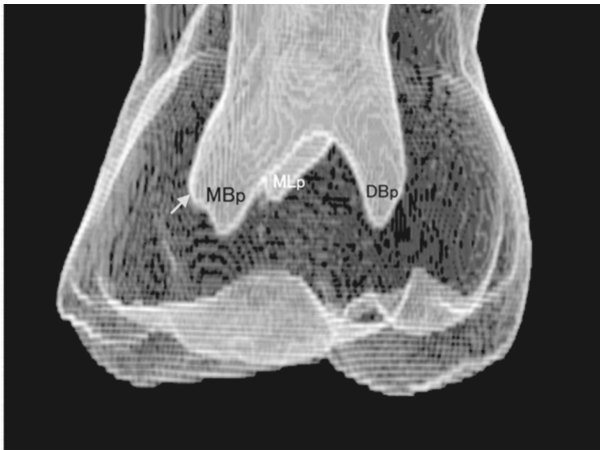

Figure 5 3D topographic relationship of the crown contour and the pulp chamber from buccal aspect in the deciduous dentition.

MBp: mesiobuccal pulp horn DLp: distolingual pulp horn MLp: mesiolingual pulp horn arrow: eminent swelling of the mesial wall in the mesiobuccal pulp horn

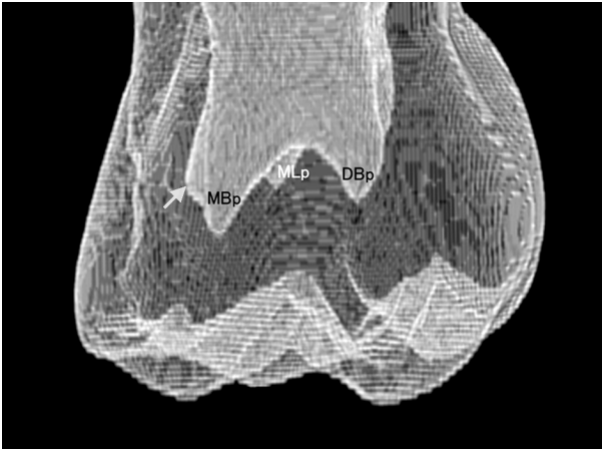


Figure 6 3D topographic relationship of the crown contour and the pulp chamber from buccal aspect in the mixed dentition.

MBp: mesiobuccal pulp horn DLp: distolingual pulp horn MLp: mesiolingual pulp horn arrow: eminent swelling of the mesial wall in the mesiobuccal pulp horn

The volume ratio of the pulp chamber to the total crown

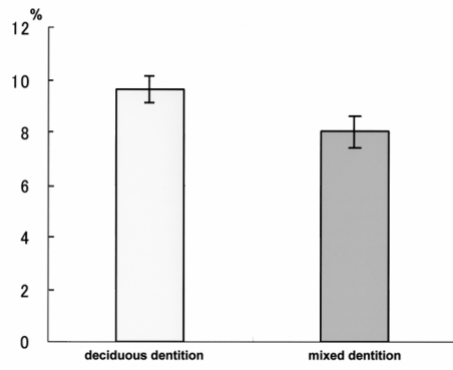


Figure 7 The volume ratio of the pulp chamber.

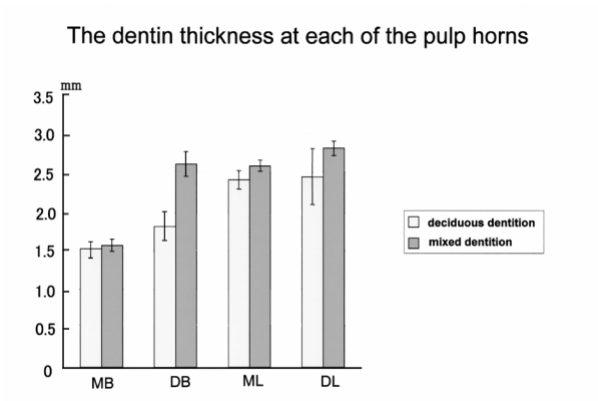


Figure 8 The thickness of the dentin.

MB: mesiobuccal pulp horn DB: distobuccal pulp horn

ML: mesiolingual pulp horn DL: distolingual pulp horn