

Title	Outcome of Lamellar Graft Patching for the Treatment of Noninfectious Corneal Perforations
Author(s) Alternative	Suzuki, T; Yamaguchi, T; Tomida, D; Fukui, M; Shimazaki, J
Journal	Cornea, 41(9): 1122-1128
URL	http://hdl.handle.net/10130/6187
Right	<p>Copyright © 2021 The Author(s). Published by Wolters Kluwer Health, Inc.</p> <p>This is an open access article distributed under the terms of the Creative Commons Attribution-Non Commercial-No Derivatives License 4.0 (CCBY-NC-ND), where it is permissible to download and share the work provided it is properly cited. The work cannot be changed in any way or used commercially without permission from the journal.</p>
Description	

Outcome of Lamellar Graft Patching for the Treatment of Noninfectious Corneal Perforations

Takanori Suzuki, MD,¹ Takefumi Yamaguchi, MD, PhD, Daisuke Tomida, MD, PhD, Masaki Fukui, MD, PhD, and Jun Shimazaki, MD, PhD

Purpose: The aims of this study were to evaluate the clinical outcome of lamellar graft patching used for treating noninfectious corneal perforations and to determine the clinical factors affecting tectonic integrity.

Methods: This retrospective study includes a total of 71 eyes of 67 patients who underwent lamellar graft patching for the treatment of corneal perforations due to persistent epithelial defects secondary to limbal stem cell deficiency (LSCD, 21 eyes; 29.6%), peripheral ulcerative keratitis (17 eyes; 23.9%), neurotrophic keratitis due to herpes simplex keratitis (HSK, 14 eyes; 19.7%), and other causes (19 eyes; 26.8%). We evaluated the tectonic integrity of the globe, visual outcomes, and postoperative complications.

Results: Tectonic integrity was achieved in 53 eyes (74.6%). The survival proportions of eyes that achieved clear grafts were 77.8% and 65.2% at 12 and 24 months, respectively. Graft failure was observed in 19 eyes (26.8%). The survival rate of tectonic integrity and eyes that finally achieved a clear graft was significantly worse in eyes with LSCD compared with those without ($P < 0.001$). The logarithm of minimal angle resolution improved significantly from 1.79 ± 0.98 to 1.22 ± 0.87 at 12 months and 1.08 ± 0.81 at 24 months. Postoperative complications included cataract formation (32 eyes, 45.1%), intraocular pressure rise (23 eyes, 32.4%), recurrent

perforations (15 eyes, 21.1%), infectious keratitis (14 eyes, 19.7%), recurrence of herpes simplex keratitis (7 eyes, 9.9%), and traumatic graft dehiscence (1 eye, 1.4%).

Conclusions: Lamellar graft patching is an effective and safe surgical treatment for noninfectious corneal perforations; however, careful attention to severe complications is necessary, especially in eyes with LSCD.

Key Words: lamellar graft patching, anterior lamellar keratoplasty, corneal perforation, herpetic keratitis, limbal stem cell deficiency

(*Cornea* 2022;41:1122–1128)

Corneal perforation is a serious sight-threatening condition caused by infectious keratitis, neurotrophic keratitis (NTK), trauma, and corneal stromal melts due to inflammatory diseases or persistent epithelial defects (PEDs). To restore eyeball integrity and avoid endophthalmitis or secondary glaucoma, proper medical and surgical interventions are needed, such as bandage contact lens, tissue glue,¹ conjunctival flap patch,² amniotic membrane transplantation,³ and penetrating keratoplasty (PKP).^{4–10} In large corneal perforations with stromal melts, tectonic PKP is the standard procedure; however, its postoperative management is often challenging.

Tectonic lamellar graft patching may be an alternate surgical procedure to tectonic PKP.¹¹ The advantages of lamellar graft patching over PKP include no risk of endothelial rejection, a lesser need for postoperative steroids, lesser incidence of glaucoma, and less risk of damage to intraocular tissues.^{11–13} However, the long-term prognosis of lamellar graft patching for corneal perforation remains elusive. We hypothesized that lamellar graft patching, rather than tectonic PKP, can be an effective surgical procedure to avoid postoperative complications, especially in noninfectious diseases. Furthermore, it is probable that the prognosis of lamellar graft patching would be valuable in different causative diseases. In this study, we focused on the cases in which we performed lamellar graft patching for corneal perforations caused by acute sterile stromal melt due to PED secondary to limbal stem cell deficiency (LSCD) by cicatricial keratoconjunctivitis, peripheral ulcerative keratitis (PUK), NTK due to herpes simplex keratitis (HSK), or other diseases. We evaluated the surgical outcomes of lamellar graft patching and assessed the tectonic integrity, clearness of the graft, visual outcome, and incidence of intraoperative and postoperative complications.

Received for publication May 12, 2021; revision received August 25, 2021; accepted September 14, 2021. Published online ahead of print November 22, 2021.

From the Department of Ophthalmology, Tokyo Dental College Ichikawa General Hospital, Chiba, Japan.

The authors have no funding or conflicts of interest to disclose.

J. Shimazaki, T. Yamaguchi, D. Tomida, and M. Fukui conducted the surgery. T. Yamaguchi and T. Suzuki assembled and analyzed the data. J. Shimazaki, T. Yamaguchi, D. Tomida, M. Fukui, and T. Suzuki discussed the data. J. Shimazaki, T. Yamaguchi, and T. Suzuki wrote the paper. All authors have read and agreed on the final version. J. Shimazaki, and T. Yamaguchi supervised this study. J. Shimazaki and T. Yamaguchi funded this study.

Supplemental digital content is available for this article. Direct URL citations appear in the printed text and are provided in the HTML and PDF versions of this article on the journal's Web site (www.corneajml.com).

The funding organization had no role in the design or conduct of this research.

Correspondence: Jun Shimazaki, MD, PhD, Department of Ophthalmology, Tokyo Dental College Ichikawa General Hospital, 5-11-13 Sugano, Ichikawa, Chiba, 272-8513, Japan (e-mail: jun@eyebank.or.jp).

Copyright © 2021 The Author(s). Published by Wolters Kluwer Health, Inc. This is an open access article distributed under the terms of the Creative Commons Attribution-Non Commercial-No Derivatives License 4.0 (CCBY-NC-ND), where it is permissible to download and share the work provided it is properly cited. The work cannot be changed in any way or used commercially without permission from the journal.

MATERIAL AND METHODS

This retrospective study was performed in accordance with the Declaration of Helsinki. It was approved by the Institutional Ethics Review Board of Tokyo Dental College Ichikawa General Hospital (I-15-40), and the need or informed consent was waived because this was a retrospective study. Patient data were anonymized before access and/or analysis.

Study Participants

We searched for patients undergoing lamellar graft patching, including deep anterior lamellar keratoplasty, at the Tokyo Dental College Ichikawa General Hospital between January 2015 and March 2020 using the Cornea Center Eye Bank database. One corneal specialist (T.S.) examined the medical records of all patients and excluded eyes that met the following criteria: corneal perforation due to acute infectious keratitis or eyes without corneal perforations (keratoconus: 43 eyes of 41 patients, corneal dystrophy: 35 eyes of 30 patients, corneal opacity due to scarring: 28 eyes of 28 patients, limbal dermoid: 17 eyes of 17 patients, and other causes such as mucous membrane pemphigoid [MMP]: 14 eyes of 14 patients). Consequently, the study included 71 consecutive eyes of 67 patients (34 eyes of 32 women and 37 eyes of 35 men) who underwent lamellar graft patching for the treatment of corneal perforations. The causes of corneal perforation included PED secondary to LSCD, PUK, NTK due to HSK, severe dry eye disease (DED), and dacryocystitis (Fig. 1). We diagnosed LSCD using slitlamp biomicroscopy under both bright light and cobalt blue light using fluorescein staining due to Stevens–Johnson syndrome, chemical burns, or MMP, as described in previous reports.^{14,15} We confirmed LSCD when the conjunctival epithelium was irregularly stained by fluorescein staining under cobalt blue light covering the entire cornea.^{14,15} NTK was defined as a decrease or absence of corneal sensation, sometimes with spontaneous epithelial breakdown, and impairment of corneal healing.¹⁶

Surgical Procedures

Under general anesthesia or retrobulbar anesthesia, lamellar graft patching was performed using layer-by-layer techniques as previously reported.^{11,17} In cases with central or paracentral perforation, the recipient cornea was cut in a circular shape by a vacuum trephine (JEDMED Co Ltd, St Louis, MO) to the deep stroma with a blade (FEATHER Safety Razor Co Ltd, Osaka, Japan), and the stromal tissue was removed using a crescent knife or spatula. Donor corneas were prepared using a Barron corneal donor punch (JEDMED Co Ltd) with a diameter of 0.25 to 0.5 mm larger than the recipient's corneal dissection size. Epithelial tissue was completely removed around the corneal perforation to prevent ingrowth. After removing the recipient's residual deep stromal tissue down to Descemet membrane, we carefully placed the donor tissue (see Supplemental video 1, Supplemental Digital Content 1, <http://links.lww.com/ICO/B323>). Therefore, we prevent epithelial tissue ingrowth into the layer between donor and recipient cornea. Single interrupted sutures were placed using 10-0 monofilament nylon (#1404; Mani, Utsunomiya, Japan, #9000G; Johnson & Johnson, New Brunswick, NJ). In eyes with peripheral perforations, such as PUK, lamellar graft patching using circular sector-shaped cryopreserved grafts was performed. After the melted corneal tissue was removed, a donor graft was sutured using 10-0 nylon sutures. Anterior iris synechiae were lysed if necessary. Subconjunctival injection of dexamethasone was administered at the end of the surgery, and a medical-use soft contact lens (AIR OPTIX EX AQUA; Alcon, Geneva, Switzerland) was placed. Either fresh (42 eyes) or cryopreserved (29 eyes) donor tissues were used appropriately. When they were available, we selected fresh donor tissues for eyes with a high risk of intraoperative PKP conversion, such as those with large perforation and severe sterile stromal lysis. Cryopreserved donor tissues were selected for patients with a low risk of PKP conversion, such as PUK and small perforations. We placed the medical-use soft contact lens or performed multilayer amniotic membrane transplantation immediately

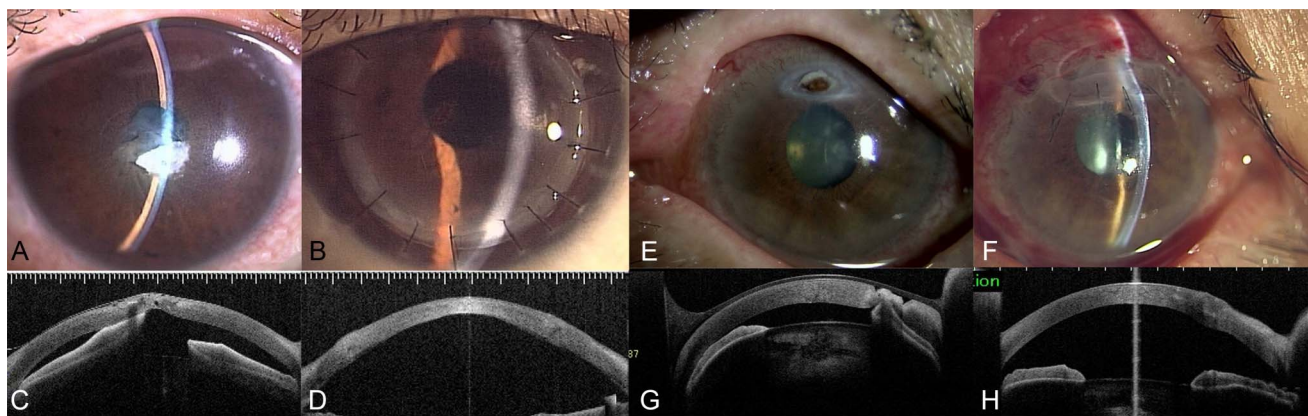


FIGURE 1. Representative cases of lamellar graft patching. A 61-year-old man (A–D) and an 84-year-old woman (E–H) were referred for the treatment of corneal perforation. Slitlamp microscopy shows a corneal perforation in the center of the cornea and a collapsed anterior chamber (A, E). Anterior segment optical coherence tomography (AS-OCT) images show a small corneal perforation (C, G). After successful lamellar graft patching (B, F), the anterior chamber shows improvement deeply enough (D, H).

after perforation before lamellar graft patching as temporizing measures. Topical antibacterial and steroid eye drops were administered postoperatively and were gradually tapered 6 months after lamellar graft patching. In cases with HSK, topical and systemic acyclovir was administered for 2 weeks after lamellar graft patching. We used each donor tissue into a single patient. Multiple uses of donor tissue were not conducted in this case series.

Data Analysis

The primary outcome measure was the tectonic integrity of the globe. A clear graft was considered when graft clarity was maintained and was regarded as the secondary outcome. Graft failure was defined as the loss of graft clarity.

We examined the best spectacle-corrected visual acuity (BSCVA) and endothelial cell density (ECD) at 3, 6, 12, 24, and 36 months postoperatively. BSCVA was measured using a standard Landolt optotype chart. The results were measured in decimal acuity and converted to the logarithm of the minimal angle of resolution (logMAR) units. We evaluated postoperative complications, such as intraocular pressure (IOP) rise, PED, and double chamber. We defined IOP higher than 21 mm Hg as increased IOP. The double chamber was defined as postoperative detachment of the recipient bed from the graft and consequently the formation of a double anterior chamber.¹⁸ ECD was measured using a specular microscopy system (EM-4000; Tomey, Nagoya, Japan) and was determined by the automated software EM-4000. In eyes in which the automated cell counts failed or misidentified endothelial cells, ECD was determined using the center method for manual counting. Residual stromal thickness was assessed using anterior segment optical coherence tomography (SS-1000, CASIA2; Tomey).

Statistical Analysis

The data were analyzed using STATA version 14 for Windows (StataCorp LP, College Station, TX) and presented as mean \pm SD for normally distributed variables. For the comparison of 2 normally distributed groups, the Student *t* test was used. Nonparametric statistical methods were used for values with a skewed distribution. For comparing 2 non-normally distributed groups, the Mann–Whitney *U* test was used, and the Wilcoxon signed-rank test was used for comparing 2 nonnormally distributed and dependent variables. Categorical variables were presented as observation counts (%) and compared between groups using the χ^2 test and Fisher exact test. Spearman correlation analysis was used to assess the correlation between logMAR and residual stromal thickness. Kaplan–Meier survival analysis was used to show graft survival in this study. We considered the difference to be statistically significant when the *P* value was <0.05 .

RESULTS

Patient Demographics and Etiology

The demographic data are summarized in Table 1. The mean follow-up period was 19.9 ± 16.8 months. The mean

TABLE 1. Demographics of Patients

Eyes	71
Patients	67
Follow-up period (mo)	19.9 ± 16.8
Sex (eyes)	
Male	37 (52.1)
Female	34 (47.9)
Age (yrs)	61.6 ± 18.7
Range	18–92
Onset to surgery (days)	16.8 ± 39.1
Number of eyes (%), mean \pm SD.	

age of the patients was 61.6 ± 18.7 years (range: 18–92 years), and the preoperative logMAR was 1.79 ± 0.98 . Lamellar graft patching was performed 16.8 ± 39.1 days after the onset of perforation. The causes of corneal perforation (Table 2) included PED secondary to LSCD caused by Stevens–Johnson syndrome, chemical burns, MMP (21 eyes, 29.6%), PUK including Mooren ulcer and others (17 eyes, 23.9%), NTK after HSV infection (14 eyes, 19.7%), severe DED (6 eyes, 8.5%), and dacryocystitis (4 eyes, 5.6%). The location of the corneal perforation was the corneal center in 51 eyes (71.8%), midperiphery in 3 eyes (4.2%), and periphery in 17 eyes (23.9%). The perforation size was less than 1 mm in 22 eyes (31.0%), 1 to 2 mm in 18 eyes (25.4%), 2 to 3 mm in 19 eyes (26.8%), and larger than 3 mm in 12 eyes (16.9%). The mean perforation diameter was 1.3 ± 1.2 mm, ranging from 0 mm to 4 mm. The mean trephined recipients' corneal diameter was 7.47 ± 1.09 mm, and the mean donor graft diameter was 7.78 ± 1.06 mm.

Outcomes of Tectonic Integrity and Clear Graft

The outcomes of the tectonic integrity and clear graft at the last visit are presented in Table 3. Tectonic integrity was achieved in all eyes immediately after lamellar graft patching and in 53 eyes of 71 eyes (74.6%) by the end of the study period. In 18 eyes (25.4%) with repeated perforations, lamellar graft patching regrafting was performed. Six eyes of 18 tectonically failed eyes (31.6%) achieved tectonic integrity, resulting in 83.1% of eyes achieving tectonic integrity by the end of the study period. The perforation size

TABLE 2. Cause for Corneal Perforation

PED secondary to LSCD by cicatricial keratoconjunctivitis	21 (29.6)
Peripheral ulcerative keratitis	17 (23.9)
NTK due to HSK	14 (19.7)
Dry eye disease	6 (8.5)
Dacryocystitis	4 (5.6)
Others	9 (12.7)
Total	71 (100)

Number of eyes (%).

TABLE 3. Outcome of Tectonic Integrity and Clear Graft

	Tectonic Integrity	Clear Graft
LSCD	10 (47.6)	8 (38.1)
PUK	14 (82.4)	15 (88.2)
HSK	13 (92.9)	14 (100)
Others	16 (84.2)	15 (78.9)
Total	53 (74.6)	52 (73.2)

Number of eyes (%), $P = 0.0003$.

was significantly smaller in eyes that achieved tectonic integrity (1.2 ± 1.1 mm) than in those that requires additional surgical procedures (1.8 ± 1.1 mm, $P = 0.03$); however, there was no significant difference in the perforation size with or without clear graft achievement (1.3 ± 1.2 vs. 1.4 ± 1.1 mm, $P = 0.25$). The location of the perforation (central or peripheral cornea) was not significantly different between eyes that achieved tectonic integrity ($P = 0.24$).

A clear graft was achieved in 77.8, 65.2, and 60.2% of eyes at 12, 24, and 36 months after surgery, respectively (Figs. 2A–C). Graft failure was observed in 19 eyes (26.8%) during the follow-up. The causes of graft failure included sterile stromalitis secondary to PED due to LSCD (13 eyes), recurrence of PUK refractory to systemic and local immunosuppressive treatment (2 eyes), and other causes (4 eyes, severe DED, etc). Nineteen eyes finally failed. Thirteen of 19 failed eyes (68.4%) had LSCD. We did not find a significant association between graft survival and either the perforation size ($P = 0.89$) or the location of the perforation ($P = 0.15$).

We then analyzed the outcomes among the different underlying causes of perforation. At the end of the study period, 10 of 21 eyes (47.6%) with LSCD, 14 of 18 eyes (82.4%) with PUK, 13 of 14 eyes (92.9%) with HSK, and 16 of 19 eyes (84.2%) with other causes achieved tectonic integrity (Table 3, χ^2 test, $P < 0.001$). Furthermore, 8 of 21 eyes (38.1%) with LSCD, 15 of 18 eyes (88.2%) with PUK, 14 of 14 eyes (100%) with HSK, and 15 of 19 eyes (78.9%) with other causes achieved a clear graft at the end of the study period. The survival rate of eyes that achieved tectonic integrity and eyes that finally achieved the clear graft was

significantly worse in eyes with LSCD compared with those without LSCD (Figs. 2B, C $P < 0.001$).

Visual Acuity and Endothelial Cell Density

BSCVA significantly improved from 1.79 ± 0.98 to 1.14 ± 0.81 at 3 months, 1.20 ± 0.88 at 6 months, 1.22 ± 0.87 at 12 months, and 1.08 ± 0.81 at 24 months (Table 4; $P = 0.002$, <0.001 , $= 0.003$, and <0.001 , respectively). The spherical equivalent was 1.47 ± 6.64 diopter (D) before lamellar graft patching, 2.26 ± 4.97 D at 3 months, 3.41 ± 5.95 D at 6 months, 2.27 ± 4.96 D at 12 months, 1.74 ± 5.67 D at 24 months, and 3.20 ± 6.35 D at 36 months ($P > 0.30$ for all). The refractive cylinder did not change significantly after lamellar graft patching ($P > 0.30$ for all). The ECD decreased from 1850.4 ± 620.0 cells/mm² preoperatively to 1741 ± 624 cells/mm² at 3 months, 1554 ± 685 cells/mm² at 6 months, 1264 ± 756 cells/mm² at 12 months, and 1375 ± 525 cells/mm² at 24 months; however, there were no significant differences between the preoperative and postoperative values. Moreover, there was no significant correlation between postoperative ECD and perforation size ($r = 0.028$, $P = 0.89$).

We assessed the clinical factors associated with BSCVA. LogMAR was not significantly associated with the perforation size (millimeter) ($P = 0.98$ at 3 months, 0.63 at 6 months, 0.12 at 12 months, 0.70 at 24 months, and 0.39 at 36 months) and the duration from onset to lamellar graft patching ($P = 0.31$ at 3 months, 0.24 at 6 months, 0.82 at 12 months, 0.36 at 24 months, and 0.75 at 36 months). There was no statistically significant difference in the final logMAR between the eyes using fresh and cryopreserved donor tissue ($P = 0.13$ at 3 months, 0.33 at 6 months, 0.36 at 12 months, and 0.43 at 24 months).

Complications

As an intraoperative complication, intraoperative Descemet membrane perforation occurred in 1 case (1.4%). As an early postoperative complication (Table 5), a double chamber was observed in 33 eyes (46.5%), which resolved spontaneously in 22 of 33 eyes (66.7%). Air

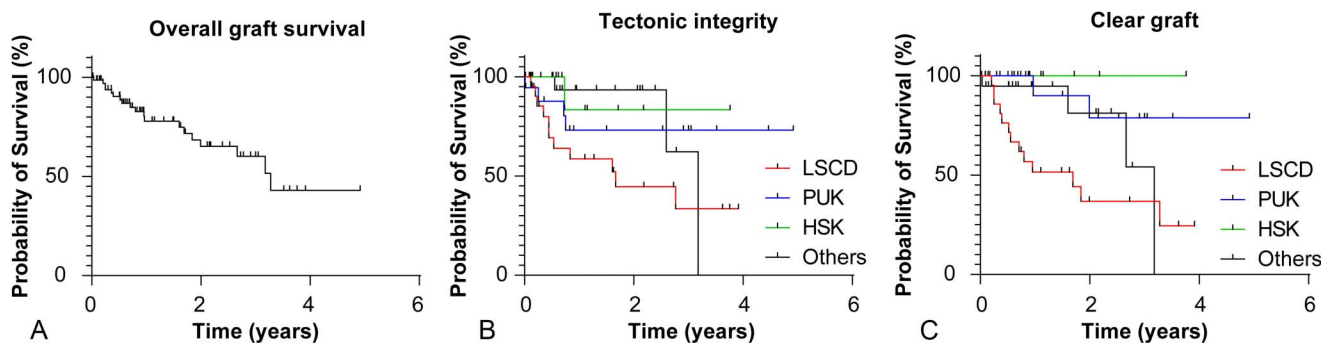


FIGURE 2. Kaplan–Meier graph showing the survival rate of eyes after lamellar graft patching. The overall survival rate of eyes that finally achieved a clear graft (A). The survival rate of tectonic integrity (B) and eyes that finally achieved a clear graft (C) in eyes with limbal stem cell deficiency ($n = 21$), peripheral ulcerative keratitis ($n = 17$), herpes simplex keratitis ($n = 14$), and others ($n = 19$).

Downloaded from http://journals.lww.com/corneajrnl by BHD/MSep/HKav1zEoum1tQINa4+kULHEZgbsH04XM10h0Cj WCCX1AWNyQp/llQrHD3i3D000dRv7TVSfI4Cj3Vc4/OAVpDda8K2+YagH515KE= on 05/31/2023

TABLE 4. Outcome of Visual Acuity, Refraction, and Endothelial Cell Density

(Eyes)	BSCVA (logMAR)	Sphere (D)	Cylinder (D)	ECD (/mm ²)
Preoperative (73)	1.79 ± 0.98	1.47 ± 6.64	5.04 ± 2.54	1850 ± 620
3 months (61)	1.26 ± 0.86	2.26 ± 4.97	6.03 ± 3.32	1741 ± 624
<i>P</i> *	0.001	0.3	0.2	0.2
6 months (46)	1.26 ± 0.90	3.41 ± 5.95	4.65 ± 2.28	1554 ± 685
<i>P</i> *	0.0007	0.3	0.9	0.6
12 months (29)	1.23 ± 0.90	2.27 ± 4.96	4.21 ± 2.26	1264 ± 756
<i>P</i> *	0.002	0.3	0.7	0.7
24 months (26)	1.04 ± 0.81	1.74 ± 5.67	5.00 ± 2.56	1375 ± 525
<i>P</i> *	0.0007	0.6	0.3	0.6
36 months (11)	1.28 ± 1.19	3.20 ± 6.35	6.45 ± 2.37	N/A
<i>P</i> *	0.09	1.0	0.1	N/A

Mean ± SD.
D: diopter, N/A: not available.
*Wilcoxon signed-rank test.
P values: compared with preoperative values.

injection was necessary in 11 eyes (33.3%), and corneal sutures were necessary in 3 eyes (9.1%). Subsequently, all cases with a double chamber eventually improved. PED occurred in 11 eyes (15.5%; 10 eyes with LSCD and 1 eye with Mooren ulcer). The most common late complication was cataract formation (32 eyes, 45.1%), followed by IOP rise (23 eyes, 32.4%); recurrent perforations (15 eyes, 21.1%); infectious keratitis (14 eyes, 19.7%), including recurrence of HSK (7 eyes, 9.9%); and traumatic graft dehiscence (1 eye, 1.4%). In 5 of the eyes that developed infectious keratitis, *Corynebacterium* was detected. Topical antibiotic treatment or repeated lamellar graft patching was performed in 2 and 3 eyes, respectively, and 1 eye each regained corneal clarity. Methicillin-resistant *Staphylococcus aureus* was detected in 1 eye, and the patient was successfully treated with topical antibiotics. Primary HSV infection occurred in 1 of 14 eyes, and topical acyclovir was administered to achieve a clear graft. Herpetic epithelial keratitis recurrence was seen in 7 of 71 eyes, and 4 of the 7 were successfully treated with topical

acyclovir, contrary to no detection of herpetic interstitial keratitis. The remaining 3 eyes developed repeated corneal perforations, and lamellar graft patching was performed repeatedly. Eventually, 1 eye achieved a clear graft, but 2 eyes failed.

The IOP rise was well controlled with topical anti-glaucoma agents or the cessation of steroid eye drops in all eyes except 1 (1.4%), which required trabeculectomy. Recurrence of perforation occurred in 8 eyes with LSCD, 3 eyes with PUK, 2 eyes with HSK, 1 eye with severe DED, and 1 eye with phlyctenular keratitis. No allograft rejection was observed. The incidences of PED, cataract formation, IOP rise, re-perforation, and infectious keratitis were significantly higher in eyes with LSCD than in those with PUK, HSK, or other causes ($P < 0.001$, $P = 0.01$, and <0.001 , respectively). There were no cases of interface epithelial ingrowth.

DISCUSSION

In this study, PED secondary to LSCD, PUK, and NTK due to HSK were the main causes of corneal perforation, accounting for approximately 70% of all perforations. We also found that the surgical outcomes of lamellar graft patching were favorable. As a surgical treatment for corneal perforation, tectonic PKP has been performed more often than lamellar graft patching. Roughly 80% to 90% of eyes reportedly achieve tectonic integrity.^{5,7-10,19} In eyes with large perforations, tectonic PKP is required; however, the overall prognosis is poor.^{10,20} Sharma et al⁸ evaluated the outcomes of tectonic PKP in 506 eyes with microbial keratitis in India and found that the visual acuity was poor if a perforation was present, whereas anatomical restoration was achieved in 454 of 506 eyes (89.7%). The long-term graft survival after tectonic PKP in corneal perforation is reportedly 67% to 73%, and graft failure is often associated with endothelial rejection or the recurrence of infectious keratitis.⁵ Another potential advantage of lamellar graft patching over tectonic PKP is the better outcome in eyes requiring repeated surgery. Indeed, 31.6% of eyes that tectonically failed eventually achieved a clear graft with repeated lamellar graft patching.

TABLE 5. Incidence of Postoperative Complications

	Total (N = 71)	LSCD (N = 21)	PUK (N = 17)	HSK (N = 14)	Others (N = 19)	<i>P</i>
Early complications						
Double chamber	33 (46.5)	10 (47.6)	5 (29.4)	6 (42.9)	12 (63.2)	0.240
PED	11 (15.5)	10 (47.6)	1 (5.9)	0 (0)	0 (0)	<0.0001
Late complications						
Cataract formation	32 (45.1)	15 (71.4)	8 (47.1)	3 (21.4)	6 (31.6)	0.015
IOP rise (>21 mm Hg)	23 (32.4)	10 (47.6)	5 (29.4)	3 (21.4)	5 (26.7)	0.099
Recurrent perforations	15 (21.1)	9 (42.9)	3 (17.6)	2 (14.3)	1 (5.3)	0.025
Infectious keratitis	14 (19.7)	8 (38.1)	0 (0)	5 (35.7)	1 (5.3)	0.001
Recurrence of HSK	7 (9.9)	2 (9.5)	0 (0)	5 (35.7)	0 (0)	0.002
Traumatic graft dehiscence	1 (1.4)	0 (0)	0 (0)	0 (0)	1 (5.3)	0.428

Number of eyes (%).

In postoperative complications, we found that IOP rise (32%) and cataract formation (47%) were relatively common, with similar incidences as in previous reports that performed tectonic PKP.^{5,8,9,19} Postoperative transient IOP rise was observed in 23 eyes; 15 eyes (21.1%) due to steroid-induced glaucoma, 6 eyes (8.4%) due to peripheral anterior synechiae (PAS), 1 eye (1.4%) due to viscoelastic material, and 1 eye (1.4%) due to pupillary block. Steroid-induced glaucoma was resolved by cessation of topical steroid in all eyes. The IOP rise due to PAS was treated by goniosynechialysis in 5 eyes and by cyclophotocoagulation in 1 eye. Although lamellar graft patching is an anterior lamellar keratoplasty, attention should be paid to postoperative PAS. Postoperative graft rejection did not occur in any eyes in this study, although stromal rejection has been reported to occur in 6% of cases in a previous study.⁸ Compared with PKP, topical steroids are not required for a long period. Because lamellar graft patching has a low risk for graft rejection, one of the advantages of this procedure is that steroid use can be ceased in eyes with steroid-induced IOP rise.

Although the overall outcomes of lamellar graft patching were favorable in this study, we found considerable differences in the success rates with different etiologies. The graft survival rate was 73.0% in eyes without LSCD in this study, which was significantly better than that in eyes with LSCD. The survival rate was poor in eyes with LSCD because of postoperative PED and sterile stromal analysis.^{5,8,19} It should be noted that the incidences of postoperative PED, cataract, recurrent perforation, incidence of HSK, and infectious keratitis were significantly higher in eyes with LSCD than in those with other etiologies. This is probably attributed to the chronic inflammatory nature of LSCD and/or delay in epithelial regeneration. Thus, we need to pay careful attention to these complications after lamellar graft patching in eyes with LSCD, and the postoperative management of delayed epithelial healing, such as therapeutic contact lens wearing or amniotic membrane patching, seems to be the key to success. However, 61.1% (11 eyes) of eyes with LSCD lost tectonic integrity after primary lamellar graft patching, and 3 of those achieved a clear graft by repeated lamellar graft patching. Although eyes with LSCD were associated with a relatively high incidence of complications, subsequent approaches, including epithelial stem cell transplantation, may be valid.

Corneal tissue is one of the most limited medical resources in the world, especially in Asian countries, because of the small number of donors and negative cultural perception of organ donation. Several techniques for lamellar keratoplasties have become the dominant surgical procedures, which have enabled multiple uses of 1 donor tissue for 2 or 3 patients. For example, the corneal endothelium can be used for Descemet membrane endothelial keratoplasty and stromal tissue can be used for deep anterior lamellar keratoplasty.²¹ Tissue adhesives, which do not require a corneal graft, have been reported to be effective for the treatment of corneal perforation. Recently, Yin et al¹ evaluated the clinical outcomes of cyanoacrylate tissue adhesive application in 140 eyes with corneal perforation due to microbial infectious keratitis, GVHD, and chemical burns and reported that the tectonic success rates were 72% at 10 days and 46% at 90

days. In this study, some patients could be successfully treated with cyanoacrylate tissue adhesive, especially patients with small corneal perforations of less than 2 mm. This study is retrospective and noncomparative with inherent bias. Future studies comparing lamellar graft patching with cyanoacrylate tissue adhesive will be required.

This study had several limitations. First, it included heterogeneous etiologies. However, because of the heterogeneity in etiology, we successfully identified risk factors for poor outcomes. Second, the indication for lamellar graft patching may not be standardized because this is a retrospective study. The selection of lamellar graft patching or tectonic PKP may also be influenced by each physician's preference and surgical experience.

In conclusion, lamellar graft patching is a safe and effective treatment for noninfectious corneal perforation, resulting in more than 80% success in achieving tectonic integrity. Compared with tectonic PKP, it seems to produce fewer postoperative complications such as graft rejection. However, eyes with LSCD should be managed cautiously because they have a higher incidence of postoperative complications.

ACKNOWLEDGMENTS

The authors thank Editage company for English language editing.

REFERENCES

1. Yin J, Singh RB, Al Karmi R, et al. Outcomes of cyanoacrylate tissue adhesive application in corneal thinning and perforation. *Cornea*. 2019; 38:668–673.
2. Korah S, Selvin SS, Pradhan ZS, et al. Tenons patch graft in the management of large corneal perforations. *Cornea*. 2016;35:696–699.
3. Grau AE, Durán JA. Treatment of a large corneal perforation with a multilayer of amniotic membrane and TachoSil. *Cornea*. 2012;31: 98–100.
4. Croghan C, Chou CY, Gajree S, et al. Emergency therapeutic penetrating keratoplasty in a tertiary ophthalmic care facility. *Eye (Lond)*. 2018;32: 655–657.
5. Hanada K, Igarashi S, Muramatsu O, et al. Therapeutic keratoplasty for corneal perforation: clinical results and complications. *Cornea*. 2008;27: 156–160.
6. Koçluk Y, Sukgen EA. Results of therapeutic penetrating keratoplasty for bacterial and fungal keratitis. *Int Ophthalmol*. 2017;37:1085–1093.
7. Mannan R, Sharma N, Pruthi A, et al. Penetrating keratoplasty for perforated corneal ulcers under topical anesthesia. *Cornea*. 2013;32: 1428–1431.
8. Sharma N, Jain M, Sehra SV, et al. Outcomes of therapeutic penetrating keratoplasty from a tertiary eye care centre in northern India. *Cornea*. 2014;33:114–118.
9. Shi W, Liu M, Gao H, et al. Penetrating keratoplasty with small-diameter and glycerin-cryopreserved grafts for eccentric corneal perforations. *Cornea*. 2009;28:631–637.
10. Yang JW, Lin HC, Hsiao CH, et al. Therapeutic penetrating keratoplasty in severe infective keratitis using glycerol-preserved donor corneas. *Cornea*. 2012;31:1103–1106.
11. Ogawa A, Yamaguchi T, Mitamura H, et al. Aetiology-specific comparison of long-term outcome of deep anterior lamellar keratoplasty for corneal diseases. *Br J Ophthalmol*. 2016;100:1176–1182.
12. Huang OS, Mehta JS, Htoon HM, et al. Incidence and risk factors of elevated intraocular pressure following deep anterior lamellar keratoplasty. *Am J Ophthalmol*. 2016;170:153–160.
13. Musa FU, Patil S, Rafiq O, et al. Long-term risk of intraocular pressure elevation and glaucoma escalation after deep anterior lamellar keratoplasty. *Clin Exp Ophthalmol*. 2012;40:780–785.

14. Deng SX, Borderie V, Chan CC, et al. Global consensus on definition, classification, diagnosis, and staging of limbal stem cell deficiency. *Cornea*. 2019;38:364–375.
15. Le Q, Xu J, Deng SX. The diagnosis of limbal stem cell deficiency. *Ocul Surf*. 2018;16:58–69.
16. Sacchetti M, Lambiase A. Diagnosis and management of neurotrophic keratitis. *Clin Ophthalmol*. 2014;8:571–579.
17. Yamaguchi T, Ohnuma K, Tomida D, et al. The contribution of the posterior surface to the corneal aberrations in eyes after keratoplasty. *Invest Ophthalmol Vis Sci*. 2011;52:6222–6229.
18. Myerscough J, Bovone C, Mimouni M, et al. Factors predictive of double anterior chamber formation following deep anterior lamellar keratoplasty. *Am J Ophthalmol*. 2019;205:11–16.
19. Dogan C, Arslan OS. Outcomes of therapeutic and tectonic penetrating keratoplasty in eyes with perforated infectious corneal ulcer. *Turk J Ophthalmol*. 2019;49:55–60.
20. Ti SE, Scott JA, Janardhanan P, et al. Therapeutic keratoplasty for advanced suppurative keratitis. *Am J Ophthalmol*. 2007;143:755–762.
21. Sharma N, Agarwal P, Titiyal JS, et al. Optimal use of donor corneal tissue: one cornea for two recipients. *Cornea*. 2011;30:1140–1144.